

# Correction of high astigmatism using LASIK and arcuate keratotomy

Julio Ortega Usobiaga, MD, PhD<sup>1</sup>, Ana Isabel Ruiz Rizaldos, MD<sup>2</sup>, Stephan Linke, MD, PhD<sup>3</sup>, Fernando Llovet Osuna, MD, PhD<sup>4</sup>, Jaime Beltrán Sanz, MD<sup>4</sup>, Julio Baviera Sabater, MD<sup>4</sup>

**ABSTRACT:** We describe the case of a 47-year-old man who came to our center to be assessed for refractive surgery in 2007. The initial scan (instillation of 3 drops of cyclopentolate 1%) revealed a corrected distance visual acuity of 20/60 with  $+0.50 -9.50 \times 10^\circ$  in OD and 20/60 with  $+1.25 -9.50 \times 165^\circ$  in OS. We performed laser in situ keratomileusis (LASIK) in both eyes using a bicylindrical approach after marking the horizontal axis using the slit lamp. Six months later, residual astigmatism was treated with arcuate keratotomy in both eyes. To the best of our knowledge, LASIK has not been previously applied in a patient with such a high degree of astigmatism. In addition, no complications were observed and the patient was satisfied with the outcome of treatment.

**KEY WORDS:** LASIK, high astigmatism.

*J Emmetropia 2012; 3: 23-26*

## INTRODUCTION


Surgical options for the correction of astigmatism include single processes, such as laser in situ keratomileusis (LASIK), photorefractive keratectomy (PRK), and arcuate keratotomy (AK), and combined processes, such as AK with compression sutures, transverse keratotomy, AK with PRK, and AK with LASIK. Different combinations of these techniques have been used to treat high degrees of astigmatism<sup>1</sup>.

## CASE REPORT

A 47-year-old man came to our center to be assessed for refractive surgery in 2007. The initial examination (instillation of 3 drops of cyclopentolate 1%) revealed a corrected distance visual acuity (CDVA) of 20/60 with  $+0.50 -9.50 \times 10^\circ$  in OD and of 20/60 with  $+1.25 -9.50 \times 165^\circ$  in OS. Biomicroscopy and fundus ex-

aminations were normal. Intraocular pressure was 17 mmHg in OD and 19 mmHg in OS. Mean central keratometry in OD was 44.00 D (keratometric astigmatism of  $-7.00 \times 10^\circ$ ) and 44.25 D in OS (keratometric astigmatism of  $-7.00 \times 165^\circ$ ). Corneal topography showed a symmetrical bow tie pattern in OU with no signs of corneal disease (figs. 1 and 2). Corneal thickness (ultrasound pachymetry) was 526 microns in OD and 538 microns in OS.

LASIK was recommended in both eyes. The horizontal axis was marked using the slit lamp in order to avoid improper alignment with the laser. The corneal flaps were then cut using the Moria LSK-One microkeratome (Microtech Inc., Moria, France). The H ring and the 100 micron plate were used. Intraoperative pachymetry was applied to determine the thickness of



**Figure 1.** Preoperative corneal topography of OD (Orbscan II).

Submitted: 9/29/2011

Revised: 11/6/2011

Accepted: 11/21/2011

<sup>1</sup> Clínica Baviera, Bilbao, Spain.

<sup>2</sup> Clínica Baviera, Zaragoza, Spain.

<sup>3</sup> Care Vision, Hamburg, Germany.

<sup>4</sup> Clínica Baviera, Valencia, Spain.

**Acknowledgements and Disclosure:** The authors have no proprietary interest in any of the materials mentioned in this article.

**Address:** Julio Ortega Usobiaga. Clínica Baviera. Ibáñez de Bilbao, 9. 48009 Bilbao, Spain. E-mail: jortega@clinicabaviera.com

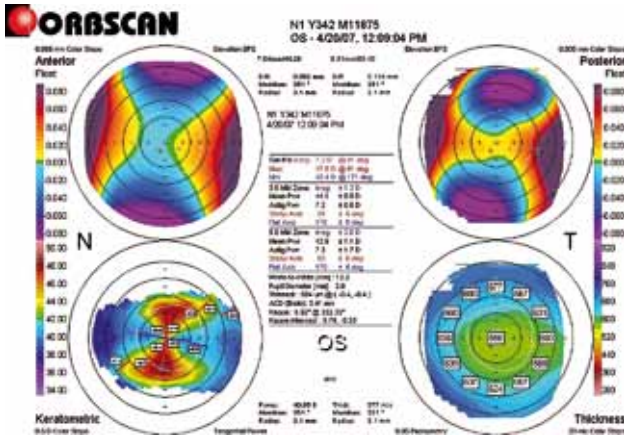


Figure 2. Preoperative corneal topography of OS (Orbscan II).

the flap. In our center, we routinely take three measurements of the corneal bed after cutting the flap. Although made carefully, measurements do vary, and we base our procedure on the thinnest one. A 54 micron flap was obtained in OD and a 128 micron flap in OS. Treatment was performed in OU following a bicyclic algorithm.

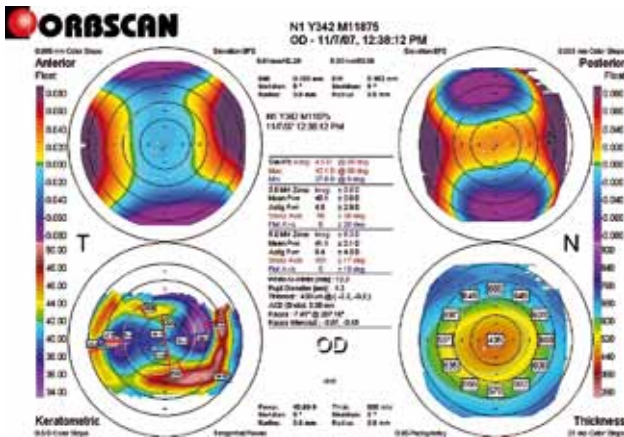


Figure 3. Postoperative corneal topography of OD (Orbscan II), 6 months after LASIK.

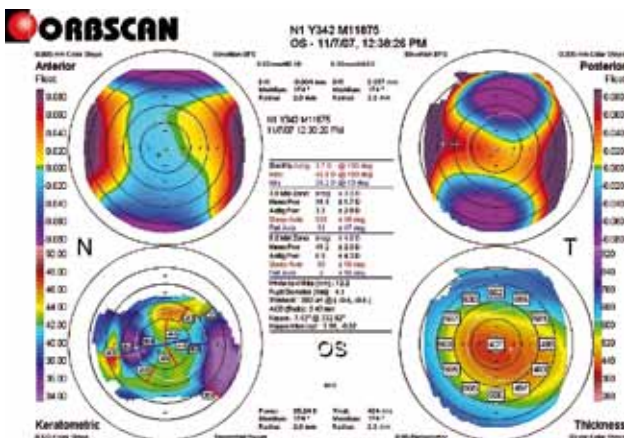


Figure 4. Postoperative corneal topography of OS (Orbscan II), 6 months after LASIK.

The laser used in OD was an Esiris excimer (Schwind, Germany); the 164 micron ablation was performed after 16,879 pulses on an optical zone (OZ) of 6.00 mm. The estimated residual bed in OD was 310 microns.

The laser used in OS was the Technolas 217z (Planoscan, Bausch & Lomb, Claremont, California, USA). An ablation of 106+86 microns in two different stages was performed: negative spherocylinder ablation ( $-2.50 -4.50 \times 165^\circ$  [106 microns on the central cornea, with OZ of 5.5 mm and 3,086 pulses]) followed by positive cylinder ablation ( $+4.50 \times 75^\circ$  [86 microns of peripheral ablation, with OZ of 6.00 mm and 1,511 pulses]). The estimated residual bed in OS was 276 microns.

Examination the following day revealed an uncorrected distance visual acuity (UDVA) of 20/30 in OU, in other words, the same as the preoperative CDVA.

Six months after LASIK, the residual cylinder was higher in OD ( $+4.00 -4.25 \times 10^\circ$ ) than in OS ( $+1.75 -2.5 \times 20^\circ$ ) (figs. 3 and 4). This refraction led us to perform AK in OU.

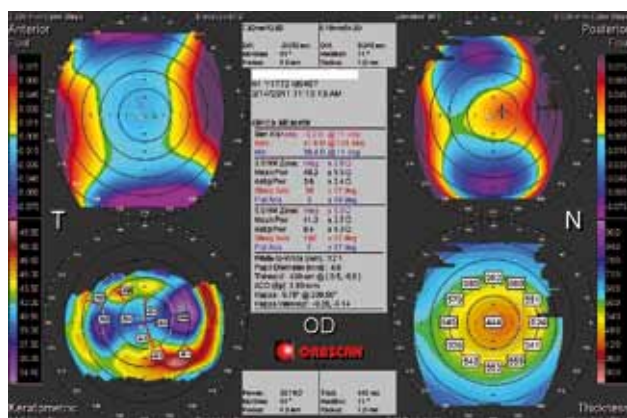
In OD, a pair of  $100^\circ$  arcuate incisions was made in a 6.00 mm OZ (3 mm long, 500 microns deep). In OS, a pair of  $110^\circ$  arcuate incisions was made in a 6.00 mm OZ (2 mm long, 500 microns deep).

A month after AK, examination revealed an UDVA of 20/30 in OD and 20/30 in OS; binocular UDVA was 20/25. CDVA was 20/25 ( $+2.50 -1.75 \times 180^\circ$ ) in OD and 20/30 in OS ( $+0.75 -1.25 \times 170^\circ$ ). Binocular CDVA reached 20/20. The mean central keratometry reading was 39.75 D (keratometric astigmatism of  $-2.25 \times 4^\circ$ ) in OD and 41.25 D (keratometric astigmatism of  $-1.75 \times 166^\circ$ ) in OS.

Four years later, at the patient's last visit, UDVA was 20/30 in OU, with binocular UDVA at 20/25. Uncorrected near (33 cm) visual acuity (UNVA) was Jaeger 9 in OD and Jaeger 7 in OS. In OD, CDVA was 20/25 ( $+2.50 -2.00 \times 5^\circ$ ) and in OS it was 20/25 ( $+1.25 -2.00 \times 180^\circ$ ); corrected near (33 cm) visual acuity (CNVA) was Jaeger 3 with the same correction. The mean central keratometry reading was 39.87 D (keratometric astigmatism of  $-4.25 \times 5^\circ$ ) in OD and 41.55 D (keratometric astigmatism of  $-4.80 \times 180^\circ$ ) in OS. Corneal topography in OU showed stability and no signs of ectasia (figs. 5 and 6). The patient was satisfied with the results of the procedure.

## DISCUSSION

Güell and Vázquez<sup>1</sup> evaluated the results obtained in the treatment of astigmatism of up to 8.00 D with AK in combination with LASIK performed at different times to profit from the additive effect of both techniques. Their results were reliable and predictable, showing that outcome is more predictable if LASIK



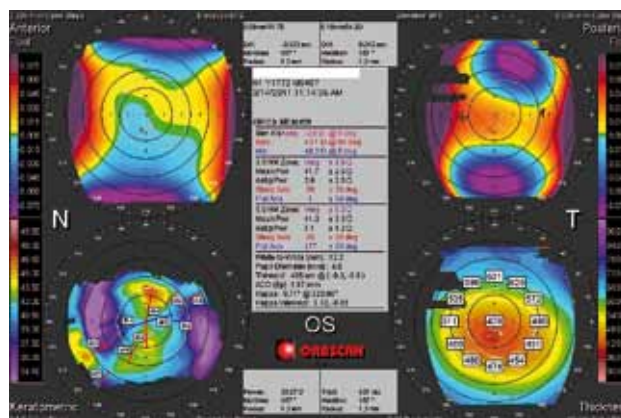**Figure 5.** Postoperative corneal topography of OD (Orbscan II), 4 years after LASIK.

is performed second in order to correct the potential residual error of AK, especially in cases with high or mixed astigmatism.

Pineda and Jain<sup>2</sup> reported a case of AK in a patient with high astigmatism due to incorrect axis treatment during LASIK. We believe that, in situations of high astigmatism, initial treatment with the excimer laser is preferable, as AK does not correct in a predictable way beyond 3.00 D<sup>3</sup>.

Variation in incision parameters can modulate the effect of AK. A wide OZ could be less likely to cause glare, and the procedure could induce less irregular astigmatism than a smaller OZ<sup>4</sup>. Although we decided to use a 6 mm OZ to increase the effect of AK, it was only moderately successful in OU. The cylinder of the OS was only reduced 1.25 D with a shift in the axis at the 1 month postoperative visit and actually increased 0.75 D with a shift in the axis at the 4 year visit. AK through the flap could behave differently than AK on virgin corneas and cause several potential complications. Incisional approaches are limited in refractive surgery, particularly in patients with high astigmatism and after cataract surgery<sup>4</sup>. Further studies are required to ascertain the limitations of AK after LASIK.

Initially, patterns for the correction of astigmatism with the excimer laser consisted of central ablation along the more curved corneal meridian, which also induces curving of the flat meridian. This effect, known as the coupling effect, induces a positive sphere, which has to be corrected in the same process of laser treatment and results in ablation of a large area of tissue<sup>5</sup>. Chayet et al.<sup>7</sup> introduced the technique of bitoric or bicylindrical cross-cylinders for the correction of myopic and mixed astigmatism. This technique curves the flat meridian while the curve meridian flattens and has the advantage of considerably reducing the amount of tissue ablated at the central cornea. Albarrán-Diego et al.<sup>7</sup> evaluated the efficacy and safety of bitoric LASIK using a Technolas 217 (Planoscan) excimer laser for the correction of mixed astigmatism. Their results in-



**Figure 6.** Postoperative corneal topography of OS (Orbscan II), 4 years after LASIK.

indicated that bicylindrical treatment is safe, predictable, and effective. As we had two different excimer lasers in our clinic, we decided to apply one on each eye to determine which the best for very high degrees of astigmatism was. The reduction in astigmatism in OD following initial LASIK was quite poor (only 50%). The correction in OS was significantly better. This leads us to believe that the Esiris (Schwind) may not be as effective as the Technolas in such cases.

When LASIK is used to treat high degrees of astigmatism, gains in CDVA are common<sup>6</sup>. In our case, three months after the procedure, CDVA had improved in OU.

Several possible causes have been proposed to explain undercorrections in the treatment of astigmatism with the excimer laser. One is the cyclotorsion that occurs in many patients while seeing with one eye instead of both. There may also be variation if the patient changes from sitting to supine position<sup>8</sup>. The amount of rotation induced is usually around 15° from that observed in supine position, typically from 2° to 7° when the patient is positioned on the laser bed. These rotations may not only produce undercorrection, but also significantly increase postoperative aberrations if they are over 2°<sup>9</sup>. Therefore, it is highly recommended to mark an axis with the patient sitting and use the slit lamp before surgery in order to prevent incorrect alignment of the eye during laser ablation, especially in the case of high-magnitude cylinders (as in our case) and when conventional treatment is performed. Such marking is routinely performed at our center and was used in the present case. Although using a mark is better than no mark, it is not the only way to perform accurate alignment. More modern excimer lasers use auto-alignment and iris registration, both of which could have improved our results.

Recent studies have compared the effectiveness of conventional LASIK treatment in corneal astigmatism and non-corneal astigmatism, also known as lens or intraocular astigmatism<sup>10</sup>. When astigmatism is corrected

following refraction or topography, both in conventional LASIK and in treatment guided by topography, the amount of iatrogenic astigmatism on the anterior corneal surface to compensate corneal astigmatism can affect postoperative visual quality. The efficacy of LASIK in the correction of astigmatism is significantly higher in eyes in which preoperative refractive astigmatism is mainly located on the anterior corneal surface, as in our patient. This may also explain why our results were so good and why the patient expressed such high satisfaction.

## REFERENCES

1. Güell JL, Vázquez M. Correction of high astigmatism with astigmatic keratotomy combined with laser in situ keratomileusis. *J Cataract Refract Surg* 2000; 26: 960-966.
2. Pineda R, Jain V. Arcuate keratotomy: An option for astigmatism correction after laser in situ keratomileusis. *Cornea* 2009; 28: 1178-1180.
3. Güell JL, Manero F, Müller A. Transverse keratotomy to correct high corneal astigmatism after cataract surgery. *J Cataract Refract Surg* 1996; 22: 331-336.
4. Choi DM, Thompson RW, Price FW. Incisional refractive surgery. *Curr Opin Ophthalmol* 2002; 13: 237-241.
5. Azar DT, Primack JD. Theoretical analysis of ablation depths and profiles in laser in situ keratomileusis for compound hyperopic and mixed astigmatism. *J Cataract Refract Surg* 2000; 26: 1123-1136.
6. Chayet AS, Montes M, Gómez L, Rodríguez X, Robledo N, MacRae S. Bitoric laser in situ keratomileusis for the correction of simple myopic and mixed astigmatism. *Ophthalmology* 2001; 108: 303-308.
7. Albarrán-Diego C, Muñoz G, Montés-Micó R, Alió JL. Bitoric laser in situ keratomileusis for astigmatism. *J Cataract Refract Surg* 2004; 30: 1471-1478.
8. Tjon-Fo-Sang MJ, de Faber JT, Kingma C, Beekhuis WH. Cyclotorsion: a possible cause of residual astigmatism in refractive surgery. *J Cataract Refract Surg* 2002; 28: 599-602.
9. Khalifa M, El-Kateb M, Shafik SM. Iris registration in wavefront-guided LASIK to correct mixed astigmatism. *J Cataract Refract Surg* 2009; 35: 433-437.
10. Kugler L, Cohen I, Haddad W, Wang MX. Efficacy of laser in situ keratomileusis in correcting anterior and non-anterior corneal astigmatism: comparative study. *J Cataract Refract Surg* 2010; 36: 1745-1752.



First author:  
Julio Ortega Usobiaga, MD, PhD

*Clinica Baviera  
Bilbao, Spain*